

Mycotoxins in poultry – External signs can give a hint



Part 2: Beak/mouth lesions

by **Marisabel Caballero** and **Inge Heinzl**, EW Nutrition

The second part of this series will focus on oral lesions as signs of mycotoxin exposure. In this segment, we will delve into the appearance and development of oral lesions, their specific locations based on the type of mycotoxin, and how toxin levels and duration of exposure impact these lesions.

A bit of history: oral lesions in poultry and their association with mycotoxin exposure

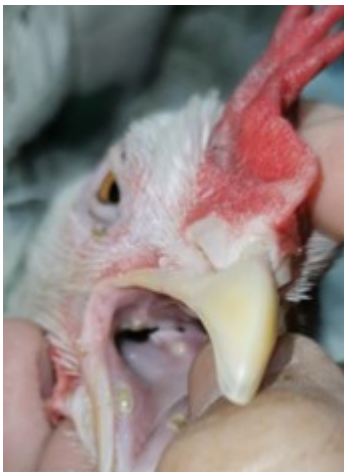Exposure to trichothecenes, a specific group of mycotoxins that includes T-2 toxin and scirpenols- such as monoacetoxyscirpenol (MAS), diacetoxyscirpenol (DAS), and triacetoxyscirpenol, has been associated with oral lesions since the early studies related with mycotoxins:

- After reports of toxicosis in farm animals, [Bamburg's group \(1968\)](#) aimed to isolate the toxins produced by *Fusarium tricinctum*, then considered the most toxic fungus found in moldy corn in Wisconsin (USA). Their experiments led to the discovery of the T-2 toxin, named after the strain of *F. tricinctum* from which it was isolated. Today, we know that this fungus was wrongly

identified; it was *F. sporotrichioides* ([Marasas et al., 1984](#)). However, the toxin remained known as T-2.

- [Wyatt's group \(1972\)](#) already described yellowish-white lesions in the oral cavity of commercial broilers in a case report from 1972. The birds also presented lesions on the feet, shanks, and heads, which raised the possibility of contact with the toxin from the litter.
- In some of the earliest experimental works regarding T-2 toxin in poultry, [Christensen \(1972\)](#) noted the development of oral necrosis in turkey poults consuming increasing levels of feed invaded by *tricinum*; also [Wyatt \(1972\)](#) found a linear increase in lesion size and severity with increasing toxin concentrations of T-2 in broilers, starting with 1 ppm. He noted that oral lesions occurred without exception in all birds receiving T-2 toxin.
- Later, [Chi and co-workers \(1977\)](#) tested what later were considered sub-acute levels of T-2 in broiler chickens, finding oral lesions from 0.4 ppm after 5 to 6 weeks of exposure. At higher levels, the lesions appeared after two weeks. In the same year, [Speers' group \(1977\)](#) concluded that adult laying hens are more tolerant to T-2 than young chicks and also found that another mycotoxin can produce oral lesions in poultry: monoacetoxyscirpenol (MAS).
- Fast forward, scientific research continued and the effects of T-2 and scirpenols, either alone or in combinations, on performance and oral lesions in poultry are today well known, as studied by [Kubena et al. \(1989\)](#), [Ademoyero & Hamilton \(1991\)](#), [Kubena et al. \(1994\)](#), [Diaz et al. \(1994\)](#), [Brake et al. \(2000\)](#), [Schuhmacher-Wolz et al. \(2010\)](#), [Verma & Swamy \(2015\)](#), [Vaccari \(2017\)](#), and reviewed by [Sokolovic et al. \(2008\)](#), [Minafra et al. \(2018\)](#), [Puvača & Ljubojević Pelić \(2023\)](#), and [Vörösházi et al. \(2024\)](#).

What are oral lesions and how do they develop?



Oral lesions caused by feed contaminated by T-2 toxin or scirpenols first occur as yellow plaques that develop into raised yellowish-gray crusts with covered ulcers ([Hoerr et al., 1982](#)). They also have been described as white in color and sometimes caseous in nature, as well as round and small, pin-point-sized, or large sheets covering a wider part of the mouth ([Wyatt et al., 1972](#); [Ademoyero and Hamilton, 1991](#)).

Under the microscope, the lesions show a fibrinous surface layer and intermediate layers with invaginations full of rods and cocci, suggesting that the surrounding microbiota quickly colonizes the lesion. Inflammation immediately ensues as [Wyatt's team \(1972\)](#) found the underlying tissues filled with granular leukocytes.

Why do T-2 toxins and other trichothecenes cause such lesions?

T-2 toxin and other trichothecenes are known for their caustic nature (evidenced by studies of [Chi and Mirocha, 1978](#); [Marasas et al., 1969](#)), and for incidents involving accidental exposure by laboratory personnel ([Bamburg et al., 1968](#), cited in [Wyatt et al., 1972](#)).

Induction of necrosis has been proposed as the main toxicity effect based on in vitro experiments on

human skin fibroblast models. The findings were a reduction of ATP production in the cell line together with disruption of mitochondrial DNA (mtDNA) but without an increase in reactive oxygen species (ROS) or activity of caspase-3 and caspase-7, which would be the case for apoptosis ([Janik-Karpinsa et al., 2022](#)). A further study ([Janik-Karpinsa et al., 2023](#)) found that T-2, on the same cell line, reduced the number of mtDNA copies, damaging several genes and hindering its function; consequently, ATP production is inhibited, and cell necrosis ensues.

Meanwhile, an inflammatory response is triggered, and the lesions are colonized by the surrounding microbial flora ([Wyatt et al., 1972](#)). Supporting this notion, [Hoerr et al. \(1981\)](#) observed no mouth lesions after directly administering toxins via crop gavage. Enterohepatic recirculation, facilitating the return of toxins to the oral cavity through saliva, can amplify their toxic effects ([Leeson et al., 1995](#)).

Oral lesions depend on...

...the toxin

Oral lesions vary depending on the type of toxin involved. The location of lesions is influenced by the specific mycotoxin in the feed. For instance, research by [Wyatt et al. \(1972\)](#) revealed that with T-2 toxin, lesions initially manifest on the hard palate and along the tongue's margins. Over two weeks, these lesions progress to affect the lingual papillae at the tongue's root, the underside of the tongue, and the inner side of the lower beak near the midline.

In contrast, [Ademoyero and Hamilton \(1991\)](#) found that scirpenols present a different pattern. A study including 4 mycotoxins at 5 different levels found, after three weeks of exposure, that the lesions caused by triacetoxyscirpenol (TAS) predominantly occurred in the angles of the mouth (53% of the birds in the study), sparing the tongue. On the other hand, diacetoxyscirpenol (DAS) primarily induces lesions inside the upper beak (shown 47% of the broilers), followed by the inside of the lower beak (in 32% of the birds). The lesion distribution for scirpentriol mirrors that of TAS, while monoacetoxyscirpenol (MAS) resembles DAS in its impact.

[Chi and Mirocha \(1978\)](#) conducted a comparative analysis of lesions caused by T-2 toxin and DAS (both 5 ppm). They observed that the severity of DAS-induced lesions was higher, leading to difficulties in mouth closure for some chicks due to encrustations in the mouth angles.

...the contamination level

Different findings regarding the dose dependency of the lesions are available. [Wyatt et al. \(1972\)](#) (Figure 1) showed a relationship between the lesion size and the toxin level. A clear relationship between the severity and incidence of lesions and the amount of T-2 toxin was also demonstrated by [Chi et al. \(1977\)](#) and [Speers et al. \(1976\)](#). This linear relationship in the case of T-2 toxin could be confirmed for the scirpenols TAS, STO, MAS, and DAS by [Ademoyero and Hamilton \(1991\)](#). They demonstrated a distinct dose-response relationship in a trial with the scirpenols STO, TAS (at 5 levels between 0-8 µg/g), MAS, and DAS (at 5 levels between 0-4 µg/g).

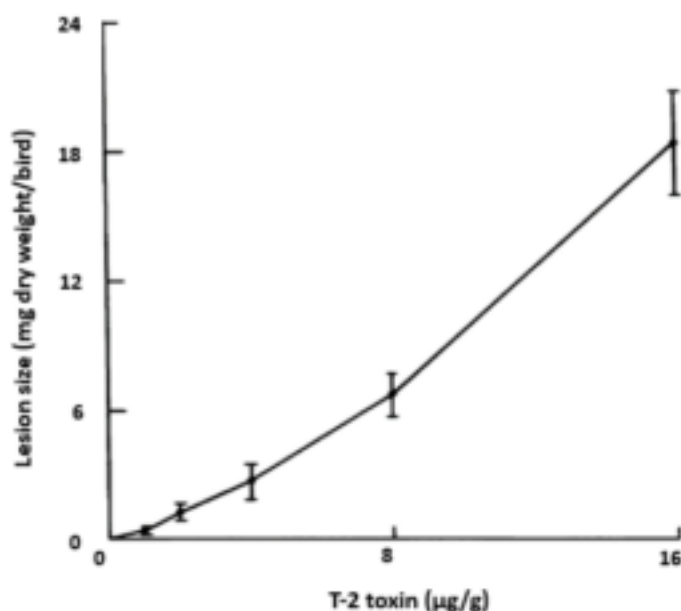


Figure 1: Effect of the inclusion rate of T-2 on the lesion size (Wyatt et al., 1972)

[Sklan et al. \(2001\)](#) tested T-2 toxin at more likely levels (0, 110, 530, and 1,050 ppb) in male chickens and found lesions in 90% of the chickens fed 500 ppb T-2 and in 100% of the ones fed 1,000 ppb of T-2 after 10 to 15 days; the higher dosage provoked the lesions of higher severity. When feeding 100 ppb of T-2, mild lesions appeared in 40% of the chickens after 25 and 35 days. Another group led by [Sklan \(2003\)](#) studied four groups of 12 one-day-old male turkey poults fed mash diets with 0 (control), 241, 485, or 982 ppb T-2 toxin for 32/33 days. Feed intake and feed efficiency were not affected, but oral lesions were apparent on day 7. The severity of the lesions plateaued after 7–15 days, and the lesion score was dose-related (see Figure 2). In the same trial, they also tested DAS (0, 223, 429, or 860 ppb) and found a similar dose relationship.

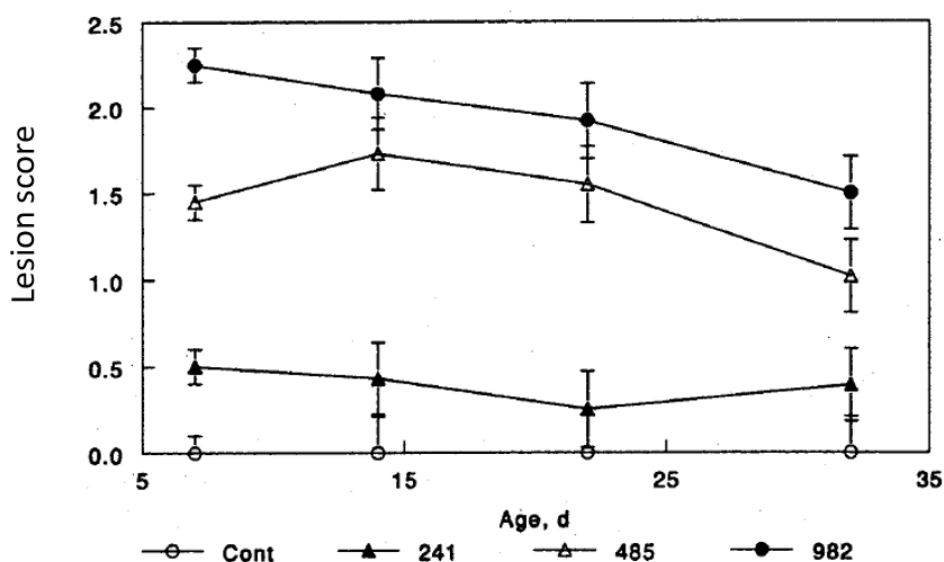


Figure 2: Lesion scores in poults fed T-2 toxin at different inclusion rates and lengths of exposure (Sklan et al., 2003)

A different result is found in the trial conducted by [Hoerr et al. \(1982\)](#), who observed lesions 2–4 days after initiating toxin exposure (T-2 toxin and DAS; 4 and 16 ppm for 21 days) and comparable lesions when feeding 50, 100, or 300 ppm of the same toxins for 7 days. They asserted that the toxin concentration did not influence the time to onset of lesions nor their severity. Most research, however, shows a clear dose-response relation.

...the duration of exposure

On one hand, chronic exposure to low levels of toxins often requires a specific duration before noticeable effects emerge. And on the other hand, symptoms may also diminish due to hormesis, an adaptive response of the organism to moderate, intermittent stress.

With high toxin levels, lesions appear very soon after exposure. For example, Diaz et al. (1994) exposed hens to a diet containing 2 mg DAS/kg feed, finding lesions in 40% of the birds after only 48 h of exposure. Chi and Mirocha (1978) noted lesions after five days with a T-2 level of 5 ppm. At a comparable level (4 ppm), [Chi et al. \(1977\)](#) reported lesions emerging in the second week of exposure, with nearly 75% of chicks experiencing oral lesions by the third week. [Sklan et al. \(2003\)](#) saw lesions already on day 7 when feeding T-2 toxin or DAS at 1 ppm.

When testing lower levels (200 ppb), [Sklan et al. \(2001\)](#) found lesions after 10 days. They became more severe after 15 to 20 days and then, their severity decreased. [Hoerr et al. \(1982\)](#) also confirmed this by reporting that the number and size of the lesions increased until day 14 but decreased thereafter. Both studies confirm the phenomenon of hormesis.

... animal factors

In general, lesions appear with lower levels of toxins in broilers compared with layers and in layers compared with breeders. Turkeys are also less sensitive than broilers ([Puvača & Ljubojević Pelić \(2023\)](#)).

Age also has an influence: young birds usually still have a maturing immune system, and the detoxification processes might not be entirely in place. However, their feed intake is lower and for this reason, in studies like [Wang and Hogan \(2019\)](#), higher impact of mycotoxins is found in older chicks.

Furthermore, additional stress factors influence the impact of mycotoxins in animals. Stress factors are cumulative and, when different factors concur, the severity of mycotoxin effects can increase.

Are oral lesions key indicators for implementing effective toxin risk management?

Oral lesions are painful for the animals, distract them from eating, and deteriorate growth performance. Often they are related with mycotoxins; however, when they appear, an investigation of different factors should take place, including mycotoxin analysis, as oral lesions may have other causes. Some of the known causes of oral lesions in poultry are also very fine feed particle size, deficiency of Vitamins A, E, B6 and Biotin, excessive levels of copper sulphate, and some parasite infections.

This article aimed to help with the differential diagnosis by providing a summary of the knowledge we have about the type and shape of the lesions related to mycotoxin contamination, which can help on a differential diagnosis. Checking the feed for mycotoxins and implementing effective toxin management helps prevent their negative effects, keeps the animals healthy, and contributes to animal welfare and, consequently, performance.

References

Ademoyero, Adedamola A., and Pat B. Hamilton. "Mouth Lesions in Broiler Chickens Caused by Scirpenol Mycotoxins." *Poultry Science* 70, no. 10 (October 1991): 2082-89. <https://doi.org/10.3382/ps.0702082>.

Bamburg, J.R., N.V. Riggs, and F.M. Strong. "The Structures of Toxins from Two Strains of *Fusarium Tricinctum*." *Tetrahedron* 24, no. 8 (January 1968): 3329-36. [https://doi.org/10.1016/s0040-4020\(01\)92631-6](https://doi.org/10.1016/s0040-4020(01)92631-6).

Bamburg, J.R., N.V. Riggs, and F.M. Strong. "The Structures of Toxins from Two Strains of *Fusarium Tricinctum*." *Tetrahedron* 24, no. 8 (January 1968): 3329–36. [https://doi.org/10.1016/s0040-4020\(01\)92631-6](https://doi.org/10.1016/s0040-4020(01)92631-6).

Brake, J., P.B. Hamilton, and R.S. Kittrell. "Effects of the Trichothecene Mycotoxin Diacetoxyscirpenol on Feed Consumption, Body Weight, and Oral Lesions of Broiler Breeders." *Poultry Science* 79, no. 6 (June 2000): 856–63. <https://doi.org/10.1093/ps/79.6.856>.

Chi, M.S., and C.J. Mirocha. "Necrotic Oral Lesions in Chickens Fed Diacetoxyscirpenol, T—2 Toxin, and Crotoxin." *Poultry Science* 57, no. 3 (May 1978): 807–8. <https://doi.org/10.3382/ps.0570807>.

Chi, M.S., C.J. Mirocha, H.J. Kurtz, G. Weaver, F. Bates, and W. Shimoda. "Subacute Toxicity of T-2 Toxin in Broiler Chicks ." *Poultry Science* 56, no. 1 (January 1977): 306–13. <https://doi.org/10.3382/ps.0560306>.

Christensen, C. M., R. A. Meronuck, G. H. Nelson, and J. C. Behrens. "Effects on Turkey Poult of Rations Containing Corn Invaded by *Fusarium Tricinctum* (CDA.) Sny. & Hans." *Applied Microbiology* 23, no. 1 (January 1972): 177–79. <https://doi.org/10.1128/am.23.1.177-179.1972>.

Diaz, G. J., E. J. Squires, R. J. Julian, and H. J. Boermans. "Individual and Combined Effects of T-2 Toxin and Das in Laying Hens." *British Poultry Science* 35, no. 3 (July 1994): 393–405. <https://doi.org/10.1080/00071669408417704>.

European Food Safety Authority. "Scientific Opinion on the Risks for Animal and Public Health Related to the Presence of T-2 and HT-2 Toxin in Food and feed1EFSA Panel on Contaminants in the Food Chain (CONTAM)." European Food Safety Authority, 2011. <https://www.efsa.europa.eu/en/efsajournal/pub/2481>.

Hoerr, F, W Carlton, B Yagen, and A Joffe. "Mycotoxicosis Caused by Either T-2 Toxin or Diacetoxyscirpenol in the Diet of Broiler Chickens." *Fundamental and Applied Toxicology* 2, no. 3 (May 1982): 121–24. [https://doi.org/10.1016/s0272-0590\(82\)80092-4](https://doi.org/10.1016/s0272-0590(82)80092-4).

Hoerr, F. J., W. W. Carlton, and B. Yagen. "Mycotoxicosis Caused by a Single Dose of T-2 Toxin or Diacetoxyscirpenol in Broiler Chickens." *Veterinary Pathology* 18, no. 5 (September 1981): 652–64. <https://doi.org/10.1177/030098588101800510>.

Janik-Karpinska, Edyta, Michal Ceremuga, Magdalena Wieckowska, Monika Szyposzynska, Marcin Niemcewicz, Ewelina Synowiec, Tomasz Sliwinski, and Michal Bijak. "Direct T-2 Toxicity on Human Skin—Fibroblast HS68 Cell Line—in Vitro Study." *International Journal of Molecular Sciences* 23, no. 9 (April 29, 2022): 4929. <https://doi.org/10.3390/ijms23094929>.

Janik-Karpinska, Edyta, Michal Ceremuga, Marcin Niemcewicz, Ewelina Synowiec, Tomasz Sliwiński, and Michal Bijak. "Mitochondrial Damage Induced by T-2 Mycotoxin on Human Skin—Fibroblast HS68 Cell Line." *Molecules* 28, no. 5 (March 6, 2023): 2408. <https://doi.org/10.3390/molecules28052408>.

Kubena, L.F., R.B. Harvey, T.S. Edrington, and G.E. Rottinghaus. "Influence of Ochratoxin A and Diacetoxyscirpenol Singly and in Combination on Broiler Chickens." *Poultry Science* 73, no. 3 (March 1994): 408–15. <https://doi.org/10.3382/ps.0730408>.

Kubena, L.F., R.B. Harvey, W.E. Huff, D.E. Corrier, T.D. Phillips, and G.E. Rottinghaus. "Influence of Ochratoxin A and T-2 Toxin Singly and in Combination on Broiler Chickens." *Poultry Science* 68, no. 7 (July 1989): 867–72. <https://doi.org/10.3382/ps.0680867>.

Leeson, Steven, Gonzalo J. Diaz, and John D. Summers. *Poultry metabolic disorders and Mycotoxins*. University Books, 1995.

Marasas, W.F.O., J.R. Bamburg, E.B. Smalley, F.M. Strong, W.L. Ragland, and P.E. Degurse. "Toxic Effects on Trout, Rats, and Mice of T-2 Toxin Produced by the Fungus *Fusarium Tricinctum* (Cd.) Snyd. Et Hans." *Toxicology and Applied Pharmacology* 15, no. 2 (September 1969): 471–82. [https://doi.org/10.1016/0041-008x\(69\)90045-3](https://doi.org/10.1016/0041-008x(69)90045-3).

Minafra, Cibele, Denise Russi Rodrigues, Isabel Cristina Mores Vaccari, Vinícius Duarte, Fabiana Ramos dos Santos, Weslane Justina da Silva, Alison Batista Vieira Silva Gouveia, Lorrayne Moraes de Paulo, Janaina Borges dos Santos, and Júlia Marixara Souza Silva. "Oral Lesions in Broilers Caused by Corn Mycotoxins: Review – Original: Lesões Orais Em Frangos de Corte Provocadas Por Micotoxinas Do Milho: Revisão." *Pubvet* 12, no. 07 (July 17, 2018). <https://doi.org/10.31533/pubvet.v12n7a134.1-11>.

O., Marasas W F, Paul E. Nelson, and T. A. Toussoun. *Toxigenic fusarium species, identity and Mycotoxicology*.

University Park: Pennsylvania State University Press, 1984.

Puvača, Nikola, and Dragana Ljubojević Pelić. "Problems and Mitigation Strategies of Trichothecenes Mycotoxins in Laying Hens Production." *Journal of Agronomy, Technology and Engineering Management (JATEM)* 7, no. 2 (April 1, 2024): 1074–87. <https://doi.org/10.55817/isad5453>.

Riahi, Insaf, Virginie Marquis, Anna Maria Pérez-Vendrell, Joaquim Brufau, Enric Esteve-Garcia, and Antonio J. Ramos. "Effects of Deoxynivalenol-Contaminated Diets on Metabolic and Immunological Parameters in Broiler Chickens." *Animals* 11, no. 1 (January 11, 2021): 147. <https://doi.org/10.3390/ani11010147>.

Schuhmacher-Wolz, Ulrike, Karin Heine, and Klaus Schneider. "Toxicity of HT-2 and T-2 Toxins." European Food Safety Authority, 2010. <https://www.efsa.europa.eu/en/supporting/pub/en-65>.

Sklan, D., E. Klipper, A. Friedman, M. Shelly, and B. Makovsky. "The Effect of Chronic Feeding of Diacetoxyscirpenol, T-2 Toxin, and Aflatoxin on Performance, Health, and Antibody Production in Chicks." *Journal of Applied Poultry Research* 10, no. 1 (March 2001): 79–85. <https://doi.org/10.1093/japr/10.1.79>.

Sklan, D., M. Shelly, B. Makovsky, A. Geyra, E. Klipper, and A. Friedman. "The Effect of Chronic Feeding of Diacetoxyscirpenol and T-2 Toxin on Performance, Health, Small Intestinal Physiology and Antibody Production in Turkey Poults." *British Poultry Science* 44, no. 1 (March 2003): 46–52. <https://doi.org/10.1080/0007166031000085373>.

Sokolović, Marijana, Verica Garaj-Vrhovac, and Borka Šlmpiraga. "T-2 Toxin: Incidence and Toxicity in Poultry." *Archives of Industrial Hygiene and Toxicology* 59, no. 1 (March 1, 2008): 43–52. <https://doi.org/10.2478/10004-1254-59-2008-1843>.

Speers, G.M., C.J. Mirocha, C.M. Christensen, and J.C. Behrens. "Effects on Laying Hens of Feeding Corn Invaded by Two Species of *Fusarium* and Pure T-2 Mycotoxin .". *Poultry Science* 56, no. 1 (January 1977): 98–102. <https://doi.org/10.3382/ps.0560098>.

Verma, Yamini, and Madhu Swamy. "Clinico-Pathological Effect of Feeding *Fusarium Sporotrichioides* and t-2 Toxin Contaminated Diet in Broiler Chicken." *Indian Journal of Veterinary Pathology* 39, no. 1 (2015): 58. <https://doi.org/10.5958/0973-970x.2015.00013.9>.

Vörösházi, Júlia, Zsuzsanna Neogrády, Gábor Mátis, and Máté Mackei. "Pathological Consequences, Metabolism and Toxic Effects of Trichothecene T-2 Toxin in Poultry." *Poultry Science* 103, no. 3 (March 2024): 103471. <https://doi.org/10.1016/j.psj.2024.103471>.

Wyatt, R. D., B. A. Weeks, P. B. Hamilton, and H. R. Burmeister. "Severe Oral Lesions in Chickens Caused by Ingestion of Dietary Fusariotoxin T-21." *Applied Microbiology* 24, no. 2 (1972): 251–57. <https://doi.org/10.1128/aem.24.2.251-257.1972>.

Wyatt, R. D., J. R. Harris, P. B. Hamilton, and H. R. Burmeister. "Possible Outbreaks of Fusariotoxicosis in Avians." *Avian Diseases* 16, no. 5 (October 1972): 1123. <https://doi.org/10.2307/1588839>.